



**PATIENT**

Aimee Cawley

**SPECIES**

Canine

**BREED**

Pomeranian

**SEX**

Female Spayed

**AGE**

3 years

**WEIGHT**

~6lbs

**INTERPRETED BY**

Maggie Machen Lamy,  
DVM, DACVIM  
(Cardiology)

**IMAGING PERFORMED BY**

A. Nicastro, DVM

**HOSPITAL NAME**

Animal Hospital of  
South Carolina

**REFERRING VET**

Dr. Stone

**INVOICE**

46116

**DATE**

12/10/25

**PRESENTING CLINICAL SIGNS**

History: Previously diagnosed with PDA – closed. Was on Pimobendan for a month but d/c per cardio.

**ELECTROCARDIOGRAPHIC FINDINGS**

A six lead ECG is available at 25mm/s; 10mm/mV. The average heart rate is 160bpm. The rhythm is sinus in origin, with a p for every QRS complex and vice versa. The P wave morphology is positive with a normal dimension. Normal PR. The QRS morphology is positive with normal dimension. MEA is normal. No ectopic beats, pauses or dysrhythmias observed.

ECG diagnosis: Normal sinus rhythm.

**ECHOCARDIOGRAM FINDINGS**

2D, m-mode, color flow and doppler imaging is available. Mild MV thickening with no prolapse into the left atrial lumen. No obvious mitral regurgitation with a normal left atrial dimension. Normal LV diameter with adequate myocardial function. The tricuspid valve appears normal with no tricuspid regurgitation. Normal right atrial and ventricular diameter and morphology indicating no overt evidence of pulmonary arterial hypertension. The pulmonic and aortic valves are normal in morphology and mobility. Normal pulmonic and aortic outflow velocities with laminar flow. No obvious aortic and trace pulmonic insufficiency. No pericardial or pleural effusion noted. No obvious cardiac masses.

**CARDIAC CHART**

CANINE CARDIAC PARAMETERS	MR VMAX (m/s)	TR VMAX (m/s)	LA/AO (Boon method)	LA/AO (Heart Base; Swe)	FS (%)	EF (%)	EPSS (cm)
NORMAL PARAMETER	4.5-5.5	<2.7	1.3	<1.6	28-40	40-100	<0.6
PATIENT	NA	NA	NM	1.3	36	70	0.2
CANINE CARDIAC PARAMETERS	HR (BPM)	AV VMAX (m/s)	PV MAX (m/s)	BODY WEIGHT (kg)	LA 2D short axis Base view (cm)	LVIDd Avg; 2D and m-mode short axis (cm)	LVIDs Avg; 2D and m-mode short axis (cm)
NORMAL PARAMETER	50-100	0.7-1.7	0.7-1.6	BELOW	BELOW	BELOW	BELOW
PATIENT	NM	1.2	1.3	2.7	1.6	2.2	1.4
*Normal chamber parameters expressed as a mean value (SD)				3	1.27 (5.3)	2.46 (2.46)	1.36 (5.5)
<b>BODY WEIGHT DEPENDENT PARAMETERS</b>				5	1.40 (4.5)	2.74 (5.2)	1.60 (4.7)
*Note: All measurements based upon multi-modal images and methods. An average value is reported.				10	1.50 (3.8)	3.27 (3.5)	2.06 (3.1)
				15	1.83 (2.0)	3.71 (2.4)	2.43 (2.1)
				20	2.02 (1.9)	4.14 (2.2)	2.80 (2.0)
				25	2.18 (2.4)	4.48 (2.9)	3.10 (2.5)
				30	2.33 (3.3)	4.83 (3.9)	3.39 (3.4)
				35	2.48 (4.3)	5.17 (5.0)	3.69 (4.5)
				40	2.62 (5.2)	5.48 (6.1)	3.96 (5.4)
				50	2.88 (7.1)	6.07 (8.3)	4.46 (7.4)

Adapted from June Boon, Veterinary Echocardiography, 1998  
Rishniw M and Hollis NE, J Vet Intern Med 2000; 14:429-435  
Hansson et al, Vet Rad and Ultrasound 2002  
Bonagura et al. Echocardiography: principles of interpretation, Vet Clin North Am 15:1177, 1995



**PATIENT**

Aimee Cawley

**SPECIES**

Canine

**BREED**

Pomeranian

**SEX**

Female Spayed

**AGE**

3 years

**WEIGHT**

~6lbs

**INTERPRETED BY**

Maggie Machen Lamy,  
DVM, DACVIM  
(Cardiology)

**IMAGING PERFORMED BY**

A. Nicastro, DVM

**HOSPITAL NAME**

Animal Hospital of  
South Carolina

**REFERRING VET**

Dr. Stone

**INVOICE**

46116

**DATE**

12/10/25

**INTERPRETATION OF THE FINDINGS & FURTHER RECOMMENDATIONS**

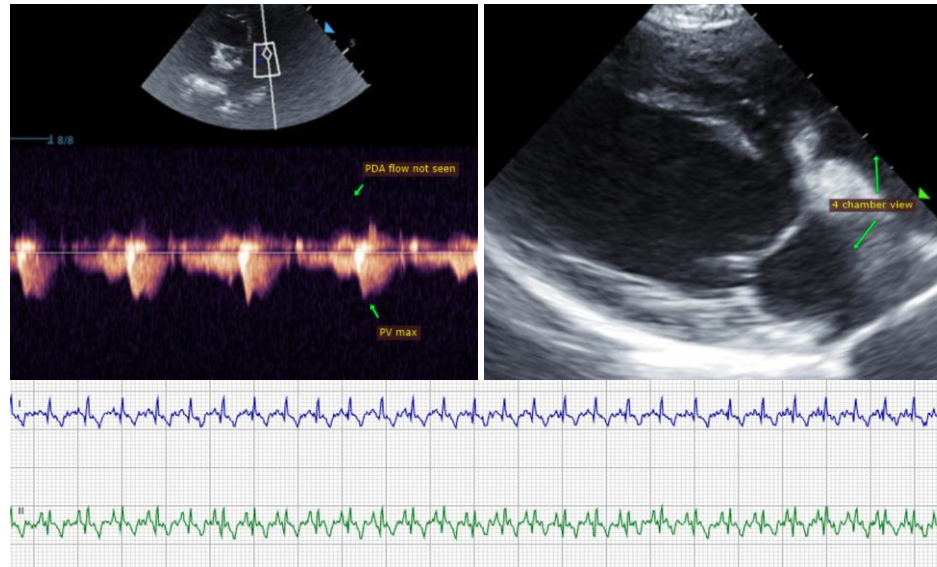
No residual flow is identified in the region of the ductus arteriosus, which likely suggests complete closure was achieved. Additionally, the left heart dimensions are normal with no dilation or dysfunction appreciated. This is great news and likely reflects a good to excellent long-term prognosis. The ECG is unremarkable with a normal sinus rhythm.

Given these findings, no medications is indicated at this time. Monitor for development of a heart murmur or signs associated with cardiac disease. This breed is predisposed to developing age-related disease going forward and serial monitoring is advised.

No cardiac contraindication for general anesthesia based upon these findings.

A recheck echocardiogram is recommended should a murmur develop in the future.

**IMAGES**



The information and recommendations provided are based on the images presented by the referring veterinarian. No evaluation can be communicated regarding pathology that was not visible in the image/video clips provided.

Thank you for this referral. This report was generated using transcription software, and minor dictation errors may be present. If the clinical or image interpretation does not parallel your findings or if I can be of any further assistance, please contact me.

**Maggie Machen Lamy, DVM**  
Diplomate of the American College of Veterinary Internal Medicine (Cardiology)  
info@sonopath.com